

Tracheoesophageal fistula following disc battery ingestion and foreign body impaction

Ahmad Khaleghnejad Tabari (MD)¹
Alireza Mirshemirani (MD)¹
Mohsen Rouzrokh (MD)¹
Javad Seyyedi (MD)¹
Nasibeh Khaleghnejad Tabari (MD)¹
Sajad Razavi (MD)¹
Mahshid Talebian (BS)¹

1- Pediatric Surgery Research Center, Mofid Children's Hospital, Shahid Beheshti University of Medical Sciences, Tehran, Iran.

* **Correspondence:**
Ahmad Khaleghnejad Tabari, Pediatric Surgery Research Center, Mofid Children's Hospital, Shahid Beheshti University of Medical Sciences, Tehran, Iran.

E-mail: khalegh@ams.ac.ir
Tel: 0098 21 22908181
Fax: 0098 21 22908181

Received: 16 June 2011
Revised: 15 Jul 2011
Accepted: 23 Aug 2011

Abstract

Background: Ingestion of foreign bodies may result in the formation of a tracheoesophageal fistula (TEF), which causes severe morbidity in children. We describe four cases of TEF, who underwent emergent surgery for repair.

Case presentation: In this report, we present about four patients aged between 9 months to 2.5 years, who referred due to disc battery ingestion. There were two boys and two girls. The common symptoms were cough, cyanosis, and dysphagia, choking and vomiting. The diagnosis was performed through an x-ray, barium swallow and CT scan. All batteries were impacted in the esophagus, two in upper, one in the middle, and one in lower esophagus position. All disc batteries were removed endoscopically, but had tracheoesophageal fistula (TEF). All the patients underwent TEF repaired surgically. There was no morbidity in four patients, but one patient developed moderate esophageal stenosis, which was repaired by staged dilatation. There was no mortality in our cases.

Conclusion: Long-term impaction of foreign bodies may result in tracheoesophageal fistula. This complication may be seen earlier with alkaline disc batteries. Removal of these foreign bodies should be followed carefully for the diagnosis and treatment of these fistulas.

Key words: Esophageal foreign body, Disc battery, tracheoesophageal fistula, Children.

Caspian J Intern Med 2011; 2(4): 336-339

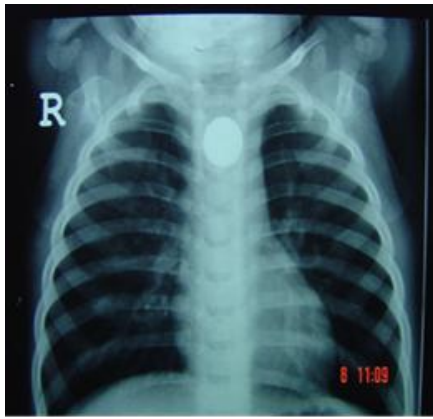The incidence of ingestion of button batteries has increased during the past several years as the availability of these devices has increased (1). More than 90% of swallowed batteries pass through the gastro-intestinal tract and do not cause a problem. The narrowest area within the GI tract is the esophagus; therefore, the commonest site of foreign body impaction is the esophagus.

An esophageal foreign body may lodge in three distinct sites: thoracic inlet, aortic arch area, and the gastroesophageal (GE) junction, and the commonest site of impaction is in the thoracic inlet followed by the GI junction and then the aortic arch. If a battery gets impacted in the esophagus, it may penetrate the esophageal wall, and causes a trachea-esophageal fistula (TEF) (2, 3).

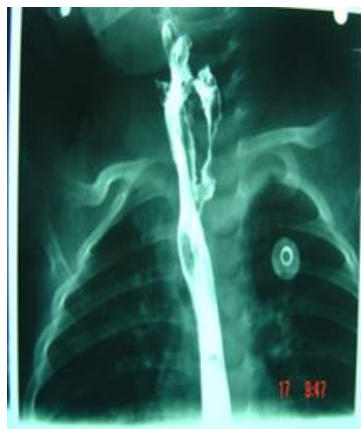Thus, early diagnosis and extraction of the battery is very important. Flexible versus rigid endoscopy for removal of foreign body impaction in the esophagus is very helpful (4). The risk of development of TEF increases after the ingestion. The symptoms of TEF include: food aspiration, fever, cyanosis, mediastinitis, pneumonia, and respiratory distress (5). The first step in suspected foreign body ingestion is a chest x-ray, and in case of more than several hours, it is recommended to perform a radiographic contrast test to rule out perforation (6). In some cases, an esophageal foreign body may cause a mediastinal mass, which can be diagnosed by a chest x-ray. Thoracotomy and fistula repair is a routine approach.

Cases presentation

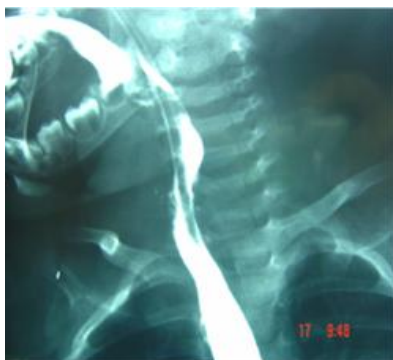Case 1- A 9-month old boy with a 5 day cough and cyanosis showed a chest x-ray foreign body (5mm) disc battery in proximal esophagus. The battery was removed by laryngoscopy. The patient continued to suffer from cough, dyspnea, and cyanosis. The physical examination revealed bilateral coarse crackles. Barium swallow showed a TEF in the upper esophagus. The fistula was repaired successfully and no evidence of TEF was found in the follow-up barium swallow.



Pre op. chest X-ray

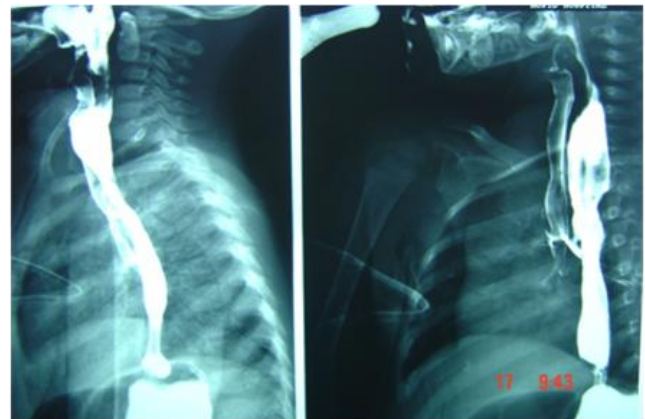

Pre Op. Barium Swallow

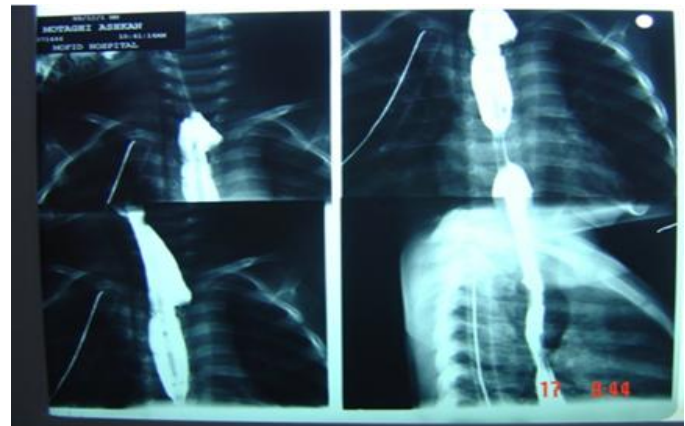

Post-Op Barium Swallow

Case 2- A 2.5-year old boy was admitted with a history of vomiting after ingestion of solid food and productive coughs for eight months. Barium swallow suggested a foreign body and chest x-ray showed a density in the lower esophagus. CT-scan showed a foreign body in the lower esophagus with possible penetration into the right bronchus. The foreign body was removed during esophagoscopy. A thoracotomy with TEF repair was performed. No fistula was found in the post-operation follow-up barium swallow.



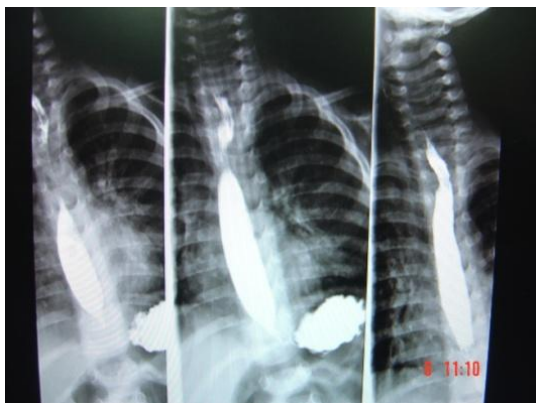
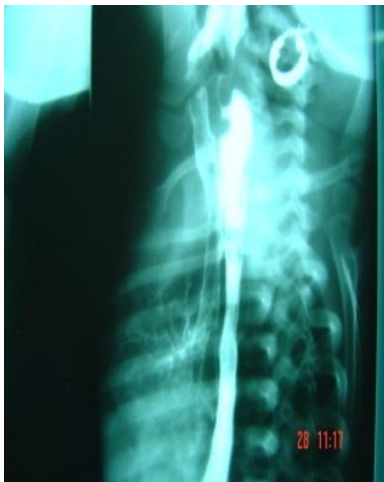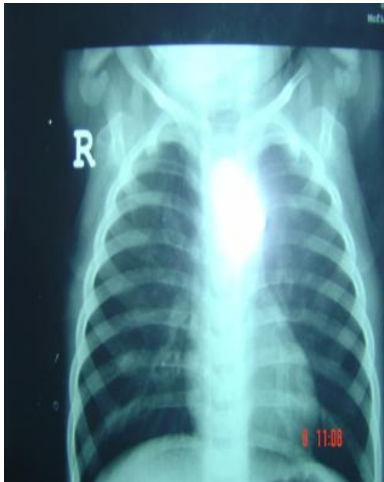Pre-Op Barium swallow with TEF



Post- OP Barium swallow without TEF

Case 3- A 2-year old girl was admitted with dysphagia and choking for eight days. A lodged battery in the esophagus was found on x-ray and was removed endoscopically; however, there was no improvement in the clinical course and the patient developed fever. Bronchoscopy was repeated and a TEF was found. Full recovery ensued after fistula repair with thoracotomy.

Case 4- A 3-year old girl was admitted due to cough, dyspnea, dysphagia, and vomiting, with the history of disc battery ingestion for 1.5 months. Chest x-ray showed foreign body at the level of upper 1/3 in esophagus. Bronchoscopy confirmed TEF, and the fistula was repaired successfully through neck incision. No fistula was found in the post-operation follow-up barium swallow in seven days time.



Discussion

Children commonly place objects in their mouths. This often results in accidental swallowing of foreign bodies. The male-to-female ratio in young children is 1:1, but in older children, boys are more commonly affected than girls (7). Foreign body ingestion is a potentially serious problem that peaks in children 6 months to 3 years of age, with the same age as in our report cases, 10-20 % of ingested foreign bodies will fail to pass through the entire gastrointestinal tract (8). Any foreign body that remains in the tract may cause obstruction, perforation or hemorrhage, and fistula formation (9). The esophagus is a passive and inadapted organ in which peristalsis may not be sufficient to pass objects that are large. For the same reason, perforation from a foreign body is more likely to occur in the esophagus than in the rest of the tract. Perforation of the esophagus is dangerous because it may lead to parapharyngeal or retropharyngeal abscess with possible descending mediastinitis. Rarely a fistula may be formed with an adjacent vessel (9).

The narrowest area within the GI tract is the esophagus. Therefore, the commonest site of foreign body impaction is the esophagus, and the commonest site of impaction is in the thoracic inlet followed by the GE junction and then the aortic arch (10). Esophageal foreign bodies can produce symptoms of dysphagia, refusal to eat, drooling, coughing, stridor, vomiting, gagging, or regurgitation. In our case series, the symptoms were cough, cyanosis, dysphagia, choking and vomiting, however, many children with esophageal foreign bodies are asymptomatic. Distal foreign bodies produce less specific symptoms (10). Classically; partially-obstructive laryngeal foreign bodies are oriented sagittally at the level of the vocal cords, while esophageal foreign bodies are oriented coronally (10).

Standard radiologic workup for suspected battery ingestion is chest film, in AP and lateral views. x-ray films have high availability, low costs and high accuracy in outlining radiopaque objects in the event of an impacted battery in the esophagus for more than several hours. It is recommended to perform a radiographic contrast test to rule out perforation, but sometimes may not be feasible because of technical difficulties and the risk of pulmonary aspiration. In these cases, CT-scan is helpful (6).

Disc battery ingestion had traditionally been feared by children as they could cause corrosive injury. A disc battery is removed endoscopically on an urgent basis if it is found to

be in the esophagus, as we removed all endoscopically in our series (10). Delayed diagnosis of an impacted battery is not uncommon, and may occasionally present a long-term complication such as perforation or trachea-esophageal fistula. The chances of perforation are very high after 8 hours of retention at a specific site (6). Thoracotomy and fistula repair is a routine approach performed for our patients.

Long-term impaction of foreign bodies may result in tracheoesophageal fistula. This complication may be seen earlier with alkaline disc batteries. Removal of these foreign bodies should be followed carefully for the diagnosis and treatment of these fistulas.

Reference

1. Chang YJ, Chao HC, Kong MS, Lai MW. Clinical analysis of disc battery ingestion in children. *Chang Gung Med J* 2004; 27: 673-6.
2. Pryor HI 2nd, Lange PA, Bader A, Gilbert J, Newman K. Multiple magnetic foreign body ingestion: a surgical problem. *J Am Coll Surg* 2007; 205: 182-6.
3. Schierling S, Snyder SK, Custer M, Pohl JF, Easley D. Magnet ingestion. *J Pediatr* 2008; 152: 294-4.
4. Gmeiner D, Von Rahden BH, Meco C, et al. Flexible versus rigid endoscop for treatment of foreign body impaction in the esophagus. *Surg Endosc* 2007; 21: 2026-9.
5. Petri NM, Mestrovic J, Andric D, Krzelj V, Stipanecvic H. Esophagotracheal fistula after lithium disc battery ingestion successfully treated with hyperbaric oxygen therapy. *Int J Pediatr Otorhinolaryngol* 2003; 67: 921-6.
6. Marom T, Goldfarb A, Russo E, Roth Y. Battery ingestion in children. *Int J Pediatr Otorhinolaryngol* 2010; 74: 849-54.
7. Conners GP. Pediatric Foreign Body Ingestion. 2010; Available at: URL: <http://emedicine.Medscape.com/article/801821-overview>. Accessed July 2010.
8. Seyedhejazi M, Sheikhzadeh D, Aliakbari Sharabiani B. Tracheo-esophageal fistula after disc battery ingestion. *J Cardiovasc Thorac Res* 2009; 1: 47-9.
9. Vijaysadan V, Perez M, Kuo D. Revisiting swallowed troubles: Intestinal complications caused by two magnets- A case report, review and proposed revision to the algorithm for the management of foreign body ingestion. *J Am Board Fam Med* 2006; 19: 511-6.
10. Dehghani N, Ludemann J. Ingested foreign Body in Children. BC Children's Hospital emergency room protocol. *BC Medical Journal*. Available at: www.bcmj.org/ingested-foreign-bodies-children-bc-children-s-hospital-emergency-room-protocol. Accessed May 2007.