

Raheleh Mehrain (MD) <sup>\*1</sup>  
Mehrdad Nabahati (MD) <sup>1</sup>

1- Department of radiology, Babol University of Medical Sciences, Babol, Iran.

\* **Correspondence:** Raheleh Mehrain, Department of Radiology, Babol University of Medical Sciences, Babol, Iran.

**E-mail:** sany\_monzavi@yahoo.com

**Tel:** 0098 111 3242151

**Fax:** 0098 111 3253061

**Received:** 16 Feb 2011

**Revised:** 20 April 2012

**Accepted:** 23 April 2012

## A case of rhabdomyosarcoma of kidney mimicking nephroblastoma

### *Abstract*

**Background:** Rhabdomyosarcoma (RMS) is one of the common malignant tumors in infants and children, but it is extremely rare in the kidney. In this paper, we present a case of RMS the kidney of a child.

**Case presentation:** A 6-month old girl presented with agitation, low fever and abdominal distention which started 5 days ago. On physical examination, the infant had a large and firm soft tissue mass in the palpation of her abdomen.

Plain abdominal x-ray, sonography and CT scan showed soft tissue mass and Doppler ultrasound demonstrated regions of vascular flow in mass. The abdominal mass was replaced and on pathological examination and immunohistochemistry the diagnosis was embryonal RMS.

**Conclusion:** Rhabdomyosarcoma of the kidney should be considered in the differential diagnosis of children with huge abdominal mass.

**Keywords:** Abdominal mass, Children, Rhabdomyosarcoma

*Caspian J Intern Med 2013; 4(1): 621-623*

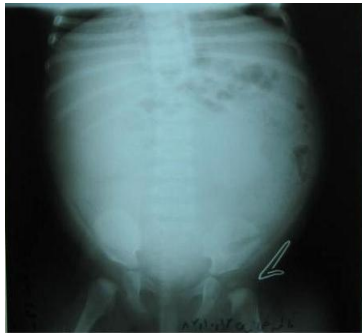**R**habdomyosarcoma (RMS) is the most common soft tissue sarcoma of the pediatric age group that contains a mixture of rhabdomyoblasts and undifferentiated cells. The head and neck and genitourinary tract are the most frequent location of RMS. Less than 20% of these tumors affect the extremities, followed by the trunk and retroperitoneum (1). RMS of genitourinary system typically affects 2-6 year old children and occurs more often in bladder and pelvic organs than kidneys (2). RMS of the kidney is extremely rare. There is still a controversy as to whether renal rhabdomyosarcoma is a distinct entity or a variant of nephroblastoma (3).

On the other hand, Wilms tumor (nephroblastoma) accounts for 87% of pediatric renal masses (4, 5). In fact, many pediatric renal tumors were previously lumped together and categorized as Wilms tumor. However, in recent years several specific tumors have been recognized as distinct pathological entities. The diagnosis of these newly described lesions can be suggested by their unique clinical history, such as age at presentation and distinctive imaging features. Knowledge of these lesions can help suggest a specific diagnosis, which in turn has implications for preoperative planning and prognosis (6). In this study, we present a case of embryonal RMS of kidney in a 6-month old girl.

### **Case Presentation**

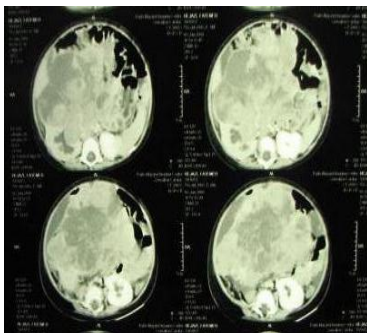
A 6-month old girl presented with agitation, low fever and abdominal distention which started 5 days ago. Past medical and family histories were unremarkable and no history of benign or malignant tumors was found in her family. On physical examination, the infant had a large and firm soft tissue mass on the palpation of her abdomen. In laboratory data, there was an increase in SGOT and SGPT and CRP and a decrease in BUN and creatinine levels.

A plain abdominal x-ray showed a huge abdominal soft tissue mass on the right side of her abdomen that displaced bowel gas to the left and occupied most of the abdominopelvic area (figure 1). On ultrasound, we found a heterogenous soft tissue mass, with 10×12×7 cm diameter, containing necrotic area. Doppler ultrasound demonstrated regions of vascular flow in mass and no flow detected in necrotic area. There was not any thrombosis in IVC and main renal veins.



**Figure 1. Abdominal x-ray shows a huge soft tissue mass in right side of the abdomen that extent to the pelvis and induces left ward displacement of bowel gas.**

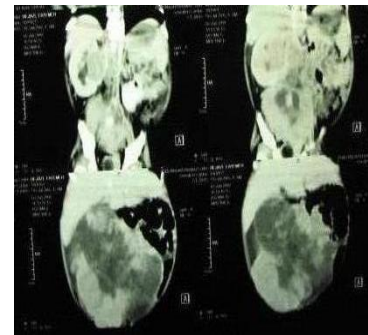
Abdominal CT scan showed a 10.5×12.2×8.3 cm heterogenous mass within the right abdomen that originated from pelvis of the right kidney and extended inferiorly to the pelvic area. It contained necrotic area with fluid density and produced mass effect on liver and bowel and induced narrowing and deviation of infrahepatic IVC (figure 2).



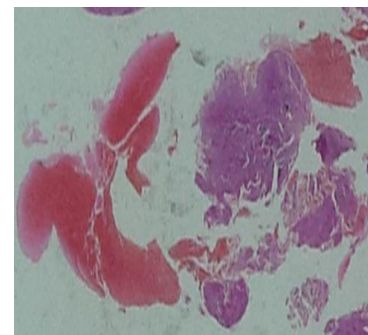
**Figure 2. Abdominal CT scan shows heterogeneous mass within the right hemiabdomen originating from the right kidney and extended inferiorly to the pelvic area and contains necrotic area with fluid density.**

The mass produced the “claw sign” of engulfment in the right kidney (figure 3). In addition, there was free fluid

around the liver and the right kidney, but there was not any evidence of lymphadenopathy and metastatic disease. The mass was removed. On pathological examination, microscopic features were neoplastic small round blue cells with a lot of nuclear mitotic features and areas of necrosis and hemorrhage (figure 4). Therefore, the diagnosis was a high grade tumor like lymphoma, rhabdoid tumor or rhabdomyosarcoma. The sample was sent for immunohistochemistry (IHC) and finally the pathological diagnosis was embryonal RMS.



**Figure 3. Abdominal CT scan shows claw sign of engulfment by the right kidney.**



**Figure 4. Microscopic features shows neoplastic small round blue cells with a lot of nuclear mitotic features and areas of necrosis and hemorrhage**

## Discussion

The clinical course and imaging findings of our patient were compatible with an aggressive tumor of the right kidney, as confirmed in the pathological examination that was embryonal rhabdomyosarcoma. Rhabdomyosarcoma (RMS) can arise virtually anywhere in the body. However, although there are 250 new cases per year in the United states (2) RMS of the kidney is extremely rare as in a research study by IRSG (Intergroup Rhabdomyosarcoma

Study Group) from 1972 till 2005, there were only 10 patients with primary renal embryonal RMS (6 cases) or undifferentiated sarcoma (4 cases) (7).

Also, Senga et al. in 1985 reported 15 cases of RMS of the kidney in Japanese literature (8). The peak incidence of RMS is 2-6 years old and 75% of patients are less than 5 years old at diagnosis. Considering that malignant striated muscle may be a component of Wilms' tumor, it can be postulated that children renal rhabdomyosarcoma represents, as a matter of fact, a tumor in which there is an overgrowth of malignant striated muscle (9). However histologically, rhabdomyoblasts are hallmark, but there are not always present especially in poorly differentiated types and histochemical markers for muscle cells are helpful (2).

Gray scale ultrasound is often the first imaging study performed to evaluate urinary symptoms. Solid tumors are typically large and heterogenous but cystic tumors are multi lobulated. Color doppler is useful in tracing displaced and compressed vessels, however, vascular invasion is unusual. CT and MRI of abdomino-pelvic are useful in determining the organ of the origin of tumor (10).

Gerard et al. in 1991 reported a case of primary retroperitoneal rhabdomyosarcoma mimicking hypernephroma in imaging. In fact, these retroperitoneal tumors may resemble renal carcinomas or tumors arising in other retroperitoneal organs (10). Unfortunately, differentiation of this tumor from other tumors of kidney on imaging is difficult and it can easily mimic other tumors of kidney in pediatric age group. Interestingly, this tumor can be engulfed by renal parenchyma and produce the claw sign on CT and MRI (figure 4). Claw sign is concavity of the renal contour with renal parenchyma cupping the tumor, and is usually described in Wilms tumor (11).

Another aggressive tumor of kidney in this age group is rhabdoid tumor. Its imaging findings and growth rate is similar to RMS of kidney. However, it can produce a peripheral subcapsular crescent with attenuation of fluid on CT in 71% of patients. It is the characteristic of Rhabdoid Tumor Kidney (RTK), although CT findings are not pathognomonic (12). Also, neuroblastoma arising in neural crest tissue of adrenal may present sonographically similar to renal masses, but it can usually be separated from a normal-appearing kidney. In conclusion, Rhabdomyosarcoma of the kidney should be considered in the differential diagnosis of children with huge abdominal mass.

## Acknowledgments

The author would like to thank Amirkola pediatric research centre.

## Conflict of Interest: None

## References

1. Kuhn JP, Slovis TL, Haller JO, Caffey's pediatric diagnostic imaging. vol. 2, 11th ed. New York: Mosby 2008; p: 2024.
2. Donnelly LF, Jones B, O'haras, Anton C, et al, editors. Diagnostic Imaging: Pediatrics. 1st ed. Salt Lake City, Utah: Amirsys 2005; pp: 5, 82.
3. Takeyama J, Watanabe M, Sato A, Hayashi Y. A case of nephroblastoma histologically mimicking rhabdomyosarcoma. *Virchows Arch* 2007; 451: 981-2.
4. Julian JC, Merguerian PA, Shortliffe LM. Pediatric genitourinary tumors. *Curr Opin Oncol* 1995; 7:265-74.
5. Ritchey ML, Azizkhan RG, Beckwith JB, Hrabovsky EE, Haase GM. Neonatal Wilms tumor. *J Pediatr Surg* 1995; 30:856-9.
6. Lowe LH, Isuani BH, Heller RM, ET AL. Pediatric Renal Masses: Wilms Tumor and Beyond. *RadioGraphics* 2000; 20: 1585-603.
7. Raney B, Anderson J, Arndt C, et al. Primary renal sarcomas in the Intergroup Rhabdomyosarcoma study group (IRSG) experience, 1972-2005: A report from the children's oncology group *Pediatr blood cancer*. 2008; 51: 339-43.
8. Senga Y, Satomi Y, Fukuda M. et al. A case of embryonal rhabdomyosarcoma of the kidney. *Hinyokika Kiyo* 1985; 31: 1013-19. [In Japanese]
9. Lifschultz BD, Gonzalez-Crussi F, Kidd JM. Renal rhabdomyosarcoma of childhood. *J Urol* 1982; 127: 309-10.
10. Gerard PS, Frank R, Wilk E, et al. Imaging of retroperitoneal rhabdomyosarcoma mimicking hypernephroma. *Clin Imaging* 1991; 15: 276-9.
11. Friedman A, Lieberman G, Radiologic Diagnosis of wilms tumor. 2008. Available at: <http://eradiology.bidmc.harvard.edu/learninglab/friedman.pdf>. Accessed. Jan 21, 2011
12. Aqrans GA, Kinqsman KD, Wagner BJ, Sotelo-Avila C. Rhabdoid tumor of the kidney in children: a comparative study of 21 cases. *AJR Am J Roentgenol* 1997; 168:447-51