

Shahla Yazdani (MD)¹
Abolhasan Alijanpoor (MD)²
Majid Sharbatdaran (MD)³
Zinatossadat Bouzari (MD)¹
Mohammad Abedisamakosh
(MD)^{*4}
Faranak Lakaieandi⁵
Mehdi Mohammadpour⁵

1- Infertility and Reproductive Health Research Center, Babol University of Medical Sciences, Babol, Iran.

2- Department of Surgery, Babol University of Medical Sciences, Babol, Iran.

3- Department of Pathology, Babol University of Medical Sciences, Babol, Iran.

4- Department of Nephrology, Mazandaran University of Medical Sciences, Sari, Iran.

5- Babol University of Medical Sciences, Babol, Iran.

* Correspondence:

Mohammad Abedi Samakosh,
Department of Nephrology,
Mazandaran University of Medical Sciences, Sari, Iran.

E-mail:

shahla_yazdani_1348@yahoo.com

Tel: 0098 111 2238284

Fax: 0098 111 2238284

Received: 19 Sep 2012

Revised: 29 April 2013

Accepted: 30 Sep 2013

Meigs' syndrome with elevated serum CA125 in a case of ovarian fibroma /thecoma

Abstract

Background: CA125 levels in Meig's syndrome can increase or be normal which an unusual laboratory condition is. In this paper, we present a case of Meigs' syndrome associated with increased CA125 level due to ovarian fibroma / thecoma.

Case presentation: A 50-year old Iranian woman presented with fever, abdominal pain and distention and in imaging assessment, a 90×109 mm heterogeneous pelvic mass with free abdominopelvic fluid was reported. Pleural effusion was detected in CXR. Aspiration of ascetic fluid showed no evidence of malignancy. CA125 level was greater than 600 IU/mL. The patient went under laparotomy in which a 120×100 mm mass was detected in her left adnexa attached to colon, bowels and bottom of pelvis. Histology reported ovarian fibro/ thecoma. The mass was resected and after that, the symptoms disappeared and CA125 level reached to 15 IU/mL. The patient had no problem after 18 months of follow up.

Conclusion: Meigs' syndrome should be considered at the differential diagnosis for a patient with pelvic mass, pleural effusion and ascites with normal cytology, increased CA125 levels.

Keywords: Meigs' syndrome, CA125, fibro/thecoma.

Citation:

Yazdani S, Alijanpour A, Sharbatdaran M, et al. Meigs' syndrome with elevated serum CA125 in a case of ovarian fibroma /thecoma. *Caspian J Intern Med* 2014; 5(1): 43-45.

Caspian J Intern Med 2014; 5(1): 43-45

Ovarian cancer is the sixth prevalent cancer in women and the most killing genital malignancy in Western Europe and northern America women (1). One type of ovarian tumor is stromal sex cord tumor which consists 5%-8% of ovarian tumors and has a subtype called fibroma / thecoma which is a benign tumor (2). Elevated serum carbohydrate antigen 125 (CA 125) levels in postmenopausal women with solid adnexal masses, ascites and pleural effusion are highly suggestive for malignant ovarian tumor. However, Meigs' syndrome which appears with these symptoms and could also have normal or increased CA125 levels is a benign condition and symptoms disappear after removal of the ovarian tumor (3, 4). We report a case of Meigs' syndrome caused by left ovarian fibroma/thecoma with elevated CA125 levels in a 50 year old woman.

Case Presentation

A 50-year old Iranian woman referred to the hospital with abdominal pain and distension, weakness, malaise and fever. With these complaints, an urgent laparotomy was carried out with diagnosis of peritonitis a month ago and in the biopsy taken, uterine fibroma was reported. Cytology of ascetic fluid was normal.

On physical examination, she had a distended abdomen with a dullness in percussion and a positive shifting dullness. In lung examination, there was a decreased breath sound at the base of left lung. In gynecological exam, cervix was normal and a pelvic mass was palpated in left adnexa. Ultrasonography reported a 90×109 mm solid mass in the left adnexa with ascitic fluid. Abdominopelvic CT scan revealed a solid heterogeneous mass in pelvic midline with ascites. In laboratory investigations, CA125 level was more than 600 IU/mL and other tumor markers were the normal range. Liver function, thyroid and kidney tests were normal. Endoscopy and colonoscopy were normal. During the first days after admission, the patient presented a generalized edema, massive ascites and dyspnea which CXR showed a pleural effusion in her left lung. For her dyspnea, she went under ascitic fluid aspiration which was negative for gram and acid fast stains. Ascitic fluid cytology showed no malignancy.

Due to clinical suspicion of malignant ovarian tumor, the patient was submitted to exploratory laparotomy. During surgery, the abdomen was opened with a midline incision. Separated collections of straw-colored fluid were between bowel loops and pelvis which were evacuated. A 100×120 cm mass with yellow color was seen in her left adnexa which was attached loosely to bowel, colon and bottom of pelvis and was removed gently sent with ascitic fluid to pathology department (figure 1).

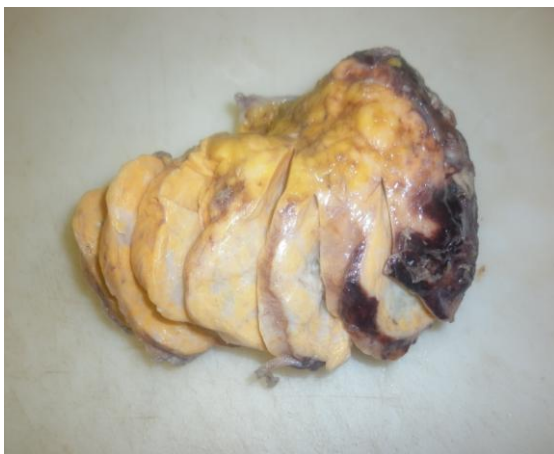

Figure 1: Macroscopic appearance of left ovarian fibroma / thecoma.

Uterus was normal and no pelvic and para-aortic lymphadenopathy was detected. Frozen section of the mass

was read as benign ovarian fibroma / thecoma. Due to tumor type, endometrial biopsy was performed in lithotomy position. Postoperative histology confirmed benign fibroma / thecoma tumor (Figure 2). Endometrial sampling was normal. After surgery, all symptoms disappeared, ascites resolved and in postoperative CXR, there was no pleural effusion and the patient was discharged from the hospital on the 7th postoperative day. During one month after surgery, CA125 level decreased to 15 IU/mL and the patient was asymptomatic 18 months after the operation.

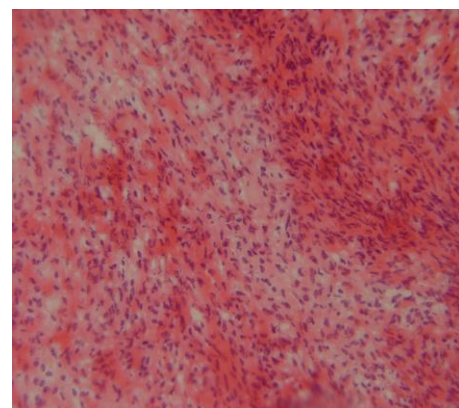


Figure 2: Microscopic appearance of left ovarian fibroma / thecoma.

Discussion

Meigs' described the association of pleural effusion and ascites with benign ovarian fibroma (5). Meigs' syndrome includes pelvic mass or benign ovarian tumor with pleural effusion (hydrothorax) and ascites which all disappear after tumor removal (4). In menopausal women, the detection of any pelvic mass with ascites, hydrothorax and high serum levels of CA125 is suggestive of a malignant ovarian tumor. However, Meigs' syndrome, as a benign condition is one of the differential diagnoses (5). Ovarian fibroma is found in 2-5% of surgically removed ovarian tumors and ascites is present in 10-15% of those with ovarian fibroma and especially with large lesion (6-8). Three cases of Meigs' syndrome with elevated CA125 levels and pathology of fibrothecoma have been reported (3).

CA125 antigen is a tumor marker produced by many clinical tissues including epithelium of the fallopian tubes, endometrium, endocervix, ovaries, and mesothelial cells of the pleura, pericardium and peritoneum (9).

It is found elevated during some physiologic conditions such as menstruation or pregnancy and in some benign conditions such as endometriosis, peritonitis, cirrhosis with ascites, PID, uterine leiomyoma, pleuritis, pericarditis and peritonitis (10-12). This tumor marker levels (normal up to 35 IU/mL) increase in malignant ovarian tumors due to inflammation associated with malignancy (13).

In conclusion, benign ovarian tumor is a rare cause for the association of pleural effusion, ascites, and pelvic mass with elevated CA125 levels. This condition suggests malignant ovarian tumor particularly in menopausal women. Therefore, for every patient referring with mentioned condition and a negative ascitic fluid cytology, we should consider Meigs' syndrome with elevated CA125 level so that treatment begins earlier and the patient's symptoms disappear after the removal of the tumor.

Acknowledgments

The authors would like to thank the patient of this case report and the ICU personnel of Ayatollah Rouhani Hospital.

Conflict of interest: There was no conflict of interest.

References

1. Parkin DM, Bray F, Ferlay J, Pisani P. Global cancer statistics, 2002. *CA Cancer J Clin* 2005; 55: 74-108.
2. Berek JS, Hacker NF. *Gynecologic oncology*. 5th ed, USA, Williams & Wilkins 2010; PP: 524-5.
3. Vieira SC, Pimentel LH, Ribeiro JC, de Andrade Neto AF, de Santana JO. Meigs' syndrome with elevated CA 125: case report. *Sao Paulo Med J* 2003; 121: 210-2.
4. Benjapibal M, Sangkarat S, Laiwejpithaya S, et al. Meigs' Syndrome with Elevated Serum CA125: Case Report and Review of the Literature. *Case Rep Oncol* 2009; 2: 61-6.
5. Meigs JV. Fibroma of the ovary with ascites and hydrothorax. *Am J Obstet Gynecol* 1954; 67: 962-85.
6. Scully RE. Ovarian tumors: a review. *Am J Pathol* 1977; 87: 686-720.
7. Abad A, Cazorla E, Ruiz F, et al. Meigs' syndrome with elevated CA 125: case report and review of the literature. *Eur J Obstet Gynecol Reprod Biol* 1999; 82: 97-9.
8. Chan CY, Chan SM, Liauw L. A large abdominal mass in a young girl. *Br J Radiol* 2000; 73: 913-4.
9. Kabawat SE, Bast RC Jr, Bhan AK, et al. Issue distribution of a coelomic-epithelium-related antigen recognized by the monoclonal antibody OC125. *Int J Gynecol Pathol* 1983; 2: 275-85.
10. Jacobs I, Bast RC Jr. The CA 125 tumour-associated antigen: a review of the literature. *Hum Reprod* 1989; 4: 1-12.
11. Kudlacek S, Schieder K, Kolbl H, et al: Use of CA 125 monoclonal antibody to monitor patients with ovarian cancer. *Gynecol Oncol* 1989; 35: 323-9.
12. O'Connell GJ, Ryan E, Murphy KJ, Prefontaine M. Predictive value of CA. 125 for ovarian carcinoma in patients presenting with pelvic masses. *Obstet Gynecol* 1987; 70: 930-2.
13. Jiang W, Lu X, Zhu ZL, Liu XS, Xu CJ. Struma ovarii associated with pseudo-Meigs' syndrome and elevated serum CA 125: a case report and review of the literature. *J Ovarian Res* 2010; 3: 18.

