

Khalid Javid Bhat (MD) ^{*1}
Sanjay Bhat (MD) ¹
Kalyan Dutt (MD) ¹
Sakul Gupta (MD) ²
Hamaad Jeelani Samoon (MD) ¹

1. Department of Medicine,
ASCOMS & Hospital, Sidhra,
Jammu, Jammu & Kashmir,
180017, India.
2. Department of Internal Medicine,
Sir Ganga Ram Hospital, New
Delhi, 110060, India.

*** Correspondence:**

Khalid Javid Bhat, Department of
Medicine, ASCOMS & Hospital,
Sidhra, Jammu, Jammu & Kashmir,
180017, India.

E-mail: drkhalidjavid@gmail.com
Tel: 0091 9469310056

Received: 8 Oct 2013

Revised: 15 May 2014

Accepted: 5 June 2014

Chronic diarrhea, eosinophilic ascites, acute pancreatitis and deep venous thrombosis: A case report

Abstract

Background: Eosinophilic gastroenteritis (EGE) is a rare inflammatory disease characterized by diffuse eosinophilic infiltration of the gastrointestinal tract with symptoms varying with the location, severity and depth of invasion. Hypereosinophilic syndrome and eosinophilic gastroenteritis overlap considerably in their pathophysiology especially if the latter is early in the clinical course and restricted to the intestinal mucosa alone.

Case presentation: A 30 year old male with chronic diarrhea and ascites presented with abdominal pain and acute lower limb swelling. The clinical presentation, peripheral hypereosinophilia and intestinal biopsy findings were all consistent with the diagnosis of EGE with eosinophilic ascites. CT abdomen and doppler imaging of the limb revealed the unusual complication of acute pancreatitis and deep vein thrombosis respectively, occurring simultaneously with EGE, making it a very rare presentation. After managing acute pancreatitis and deep vein thrombosis, the patient was treated with prednisolone 20 mg/day for four weeks and tapered slowly. His diarrhea settled and ascites resolved completely.

Conclusion: This case report emphasizes that one should consider these rare disorders during the differential diagnosis of unexplained gastrointestinal symptoms in the presence of hypereosinophilia, encompassing the 'forme frustes' of hypereosinophilic syndrome.

Keywords: Eosinophilic gastroenteritis, Acute pancreatitis, Deep vein thrombosis.

Citation:

Bhat KJ, Bhat S, Dutt K, Gupta S, Samoon HJ. Chronic diarrhea, eosinophilic ascites, acute pancreatitis and deep venous thrombosis: A case report. *Caspian J Intern Med* 2014; 5(3): 183-186.

Caspian J Intern Med 2014; 5(3): 183-186

Eosinophilic gastroenteritis (EGE), a rare disease is characterized by recurrent eosinophilic infiltration of the gastrointestinal (GI) tract leading to nonspecific GI symptoms that are usually associated with peripheral eosinophilia. It is one of the rare causes of chronic diarrhea (1). Hypereosinophilic syndrome (HES) applies to all clinical presentations in which hypereosinophilia (HE) is directly linked to tissue damage, regardless of whether HE can be ascribed to a reactive process, neoplastic process, or another underlying disease (2). There are three subtypes of EGE, mucosal, muscular, and subserosal. However, the mucosal form is the most common (3). Clinical manifestations range from non-specific gastrointestinal complaints to more specific symptoms such as protein-losing enteropathy, luminal obstruction and eosinophilic ascites. Peripheral eosinophilia is common in all subtypes of EGE and is noted in 60-80% of the patients (1). Endoscopic findings may be nonspecific and can range from erythema and friability to erosions and ulcerations. Biopsy is highly suggestive of EGE but diagnosis can be missed in up to 25% of cases (4).

Moreover, in cases where the diagnosis remains uncertain, CT imaging can help in localizing areas of thickened bowel, a potential clue to the chronic inflammation (5).

We report a case of chronic diarrhea and eosinophilic ascites, an uncommon presentation of EGE which was complicated by acute pancreatitis and deep vein thrombosis (DVT) of left lower limb simultaneously, a rare clinical association.

Case Presentation

A 30-year old male was admitted to our hospital with the complaints of epigastric pain, vomiting and swelling of his left limb for past six days. He was also having diarrhea for the last several months. Detailed history revealed that he had been reasonably evaluated for chronic diarrhea and ascites for the last six months before he sought the current consultation. There was no history of fever, jaundice, blood in the stool or any bladder symptoms. He was non-alcoholic and had no personal or family history of any allergy or asthma. On admission, the patient looked emaciated with dry skin, had oral temperature of 98⁰ F, pulse - 90 beats/min and blood pressure of 130/90 mmHg. Abdominal examination revealed periumbilical tenderness with appreciable ascites and there were no signs suggestive of chronic liver disease. He had edematous and tender swelling of his left leg with limited passive mobility. His peripheral pulses were normal. Laboratory investigations showed hemoglobin -10.7 g/dL, total leukocyte count - 10,800/mm³ with predominant eosinophils (22%), absolute eosinophil count - 2,376/mm³ (normal range, 0 to 500/mm³) and platelet count - 2.5 lakh/cumm³. Serum amylase measured 650U/L (reference range: 0-200 U/L), serum lipase -150 U/L (reference range: 30-110 U/L), serum bilirubin - 1.0 mg/dl, serum albumin - 4.5 mg/dl, aspartate transaminase - 46 IU/L, alanine transaminase - 80 IU/L and alkaline phosphatase - 42 U/L. He tested negative for HIV-1 and 2 (ELISA), HBsAg and anti-HCV antibody. Routine stool examination and fecal fat estimation of the stool was normal. Ultrasound showed moderate ascites with normal echotexture of the liver and mild oedematous pancreas. Ascitic fluid study revealed high SAAG ascites with total leukocyte count-1000/ mL, 90% of which were eosinophils (figure 1), adenosine deaminase (ADA) - 18 IU/L and amylase - 28U/L (range, 0 - 100 U/L). Serum IgE level was elevated at 548 IU/mL (normal < 180

IU/mL). Duplex color doppler of left limb showed thrombotic occlusion at the level of distal calf vein suggestive of deep vein thrombosis (DVT). Contrast enhanced CT imaging of abdomen done two days later revealed thickening of duodenum, proximal jejunal wall and presence of ascites (figure 2) with mildly enlarged pancreas (figure 3).

Once the patient was stable, upper gastrointestinal endoscopy showed mild hyperemia of antral mucosa of stomach, and duodenum. Duodenal biopsy showed normal villous pattern with mild inflammation and eosinophilic infiltration (12/HPF). To ascertain other causes of HE, bone marrow biopsy was done which revealed erythroid hyperplasia with normoblastic erythropoiesis and prominent eosinophilic infiltration (25%) (figure 4).

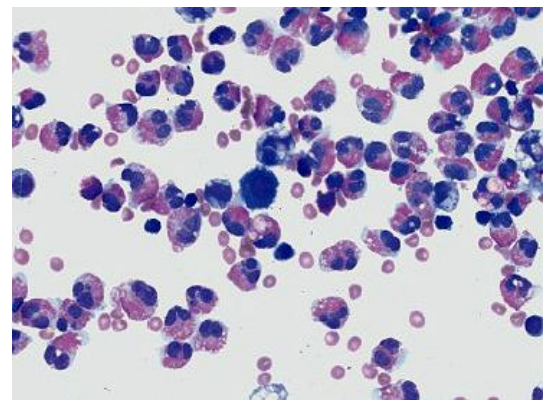


Figure 1. Ascitic fluid showing increased numbers of eosinophils with Wright-Giemsa stain (magnification x 400)

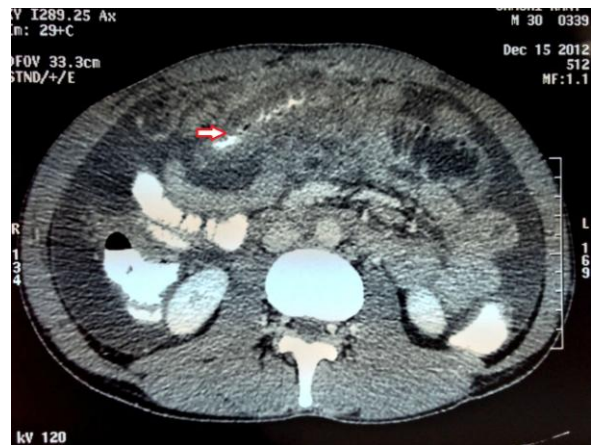

Figure 2. Contrast enhanced CT imaging of abdomen showing intestinal thickening of small gut (jejunum) and ascites.

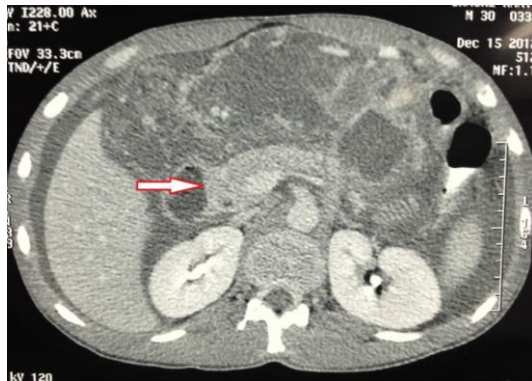


Figure 3. Contrast enhanced CT imaging of abdomen showing mild edematous pancreas.

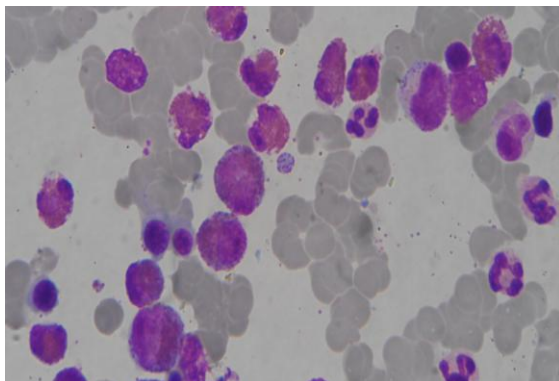


Figure 4. Bone marrow showing markedly increased number of eosinophils.(Leishman stain × 1000).

The constellation of clinical presentation, hypereosinophilia, CT and biopsy findings and an avid clinical response to steroids was highly suggestive of EGE. Acute pancreatitis was managed conservatively while DVT was treated with low molecular weight heparin and oral anticoagulants. To treat EGE and manage HE, the patient was put on oral prednisone (20mg/day) for four weeks and tapered slowly. The patient's diarrhea settled and ascites resolved completely. At follow-up, a repeat peripheral blood count showed a considerable fall in the absolute eosinophil count (300/ μ l) and the patient was doing well.

Discussion

Eosinophilic gastrointestinal disorders are exceedingly rare and manifest through all races and ages, from infancy through adulthood (6). In HES, eosinophil-induced organ damage may vary from angioedema, eczema and peripheral neuropathy to cardiac fibrosis and thrombosis. About 25% of

cases with HES, however, have eosinophilic infiltration in the gastrointestinal tract and there may be little to distinguish between EGE and HES, especially if the latter is early in the clinical course and restricted to the intestinal mucosa alone (7). After a reasonable workup, the cause of diarrhea and eosinophilic ascites in our patient seemed to be EGE which was supported further by the biopsy, CT findings and an avid clinical response to the steroid therapy. Chronic diarrhea and eosinophilic ascites are rare manifestations of EGE (1). Acute pancreatitis has also been reported previously in association with EGE (8). However, the unusual complication of acute DVT and acute pancreatitis occurring simultaneously in a patient with EGE makes it a very rare case. Initially, pancreatitis seemed to be of unclear etiology as our patient was non-alcoholic and had no history of any gall bladder disease. Nonetheless, eosinophil-induced direct toxic endothelial injury or obstruction of the pancreatic duct may explain the cause of acute pancreatitis in our case (9). Similarly DVT can be explained by endothelial dysfunction due to the degranulation of activated eosinophils (cationic protein, major basic protein) and inhibition of the natural anticoagulant pathways (thrombomodulin, heparan sulphate, and antithrombin III) (10).

The diagnosis of eosinophilic gastrointestinal disorders (EGID) should be considered in patients with history of chronic diarrhea, peripheral eosinophilia and eosinophilic ascites. Evaluation and risk determination for HES in patients with apparent EGID is also important. Our case also emphasizes the importance of being aware of the 'forme frustes' of hypereosinophilic syndrome and various complications arising from the same.

Acknowledgments

The authors thank Dr R P kudyar, Director-Principal ASCOMS and hospital for arranging the interactive sessions with the faculty of radiology and hematopathology which helped us in final framing of this manuscript.

Conflict of Interest: There is no conflict of interest.

References

1. Lee DR. A case of eosinophilic gastrointestinal disorders presenting with chronic diarrhea and abdominal pain. Korean J Fam Med 2011; 32: 257-62.

2. Valent P, Klion AD, Horny HP, et al. Contemporary consensus proposal on criteria and classification of eosinophilic disorders and related syndromes. *J Allergy Clin Immunol* 2012; 130: 607-12.
3. Rothenberg ME. Eosinophilic gastrointestinal disorders (EGID). *J Allergy Clin Immunol* 2004; 113: 11-28.
4. Talley NJ, Shorter RG, Phillips SF, Zinsmeister AR. Eosinophilic gastroenteritis: a clinicopathological study of patients with disease of the mucosa, muscle layer, and subserosal tissues. *Gut* 1990; 31: 54-8.
5. Wiesner W, Kocher T, Heim M, Bongartz G. CT findings in eosinophilic enterocolitis with predominantly serosal and muscular bowel wall infiltration. *JBR-BTR* 2002; 85: 4-6.
6. Khan S, Orenstein SR. Eosinophilic gastroenteritis: epidemiology, diagnosis and management. *Paediatr Drugs* 2002; 4: 563-70.
7. Freeman HJ. Adult eosinophilic gastroenteritis and hypereosinophilic syndromes. *World J Gastroenterol* 2008; 14: 6771-3.
8. Christopher V, Thompson MH, Hughes S. Eosinophilic gastroenteritis mimicking pancreatic cancer. *Postgrad Med J* 2002; 78: 498-9.
9. Bellaiche G, Fontaine H, Choudat L, Lusina D, Ley G, Slama JL. Pancreatic involvement, ascites and diarrhea in idiopathic hypereosinophilic syndrome. *Gastroenterol Clin Biol* 1997; 21: 519-22. [In French]
10. Kanno H, Ouchi N, Sato M, Wada T, Sawai T. Hypereosinophilia with systemic thrombophlebitis. *Hum Pathol* 2005; 36: 585-9.