

Hassan Mahmoodi Nesheli (MD)<sup>1</sup>  
Naimeh Nakhjavani(MD)<sup>1</sup>  
Tahere Galini Moghaddam (MD)<sup>\*2</sup>

1- Non-Communicable Pediatrics Disease Research center, Babol University of Medical Sciences, Babol, Iran.  
2- Department of Gynecology & Obstetrics, Mazandran University of Medical Sciences, Sari, Iran.

**\* Correspondence:**  
Tahere Galini Moghaddam, Assistant Professor of Gynecology & Obstetrics, Mazandran University of Medical Sciences, Sari, Iran.

**E-mail:**  
taheremoghaddam@yahoo.com  
**Tel:** 0098 111 3242151-5  
**Fax:** 0098 111 3240656

**Received:** 22 Oct 2010  
**Revised:** 20 March 2011  
**Accepted:** 25 May 2011

# Severe generalized muscular atrophy, nerve optic atrophy, ear problem and disability with Pelger-Huet anomaly

## Abstract

**Background:** The Pelger-Huet anomaly dominantly is a rare and benign inherited defect of terminal neutrophil differentiation. Although neutrophil migration may be minimally impaired, granulocytes function is otherwise normal association abnormalities such as ocular, musculoskeletal are reported very rare.

**Case:** An eight year-old boy with good consciousness but severe muscular atrophy and difficulty in respiration was admitted in Amirkola Hospital at Babol University of Medical Sciences Babol, Iran. The patient was febrile at presentation. The chest x-ray was normal and other causes of respiratory problem were ruled out. The patient and his mother have 30% to 40% band and Pelger-Huet cells in peripheral blood smear. He gradually has gotten hearing loss and decreased visual acuity for three years. He has optic nerve atrophy.

**Conclusion:** The patient is an unusual type of Pelger-Huet anomaly with multiple organ dysfunctions probably due to simultaneous muscular degenerative disease.

**Key words:** Pelger-Huet anomaly, Muscular atrophy, Optic nerve atrophy.

*Caspian J Intern Med 2011; 2 (2):245-248.*

In the Pelger-Huet anomaly (PHA) segmentation of the lobbing in the neutrophil leukocytes is limited. The anomaly was described first by the Pelger in 1928 as a manifestation of tuberculosis and then the recognition by Huet in 1931 as a nuclear segmentation defect. Nowadays it is called the PHA as inherited, a wide variety of morphologic variation in leukocyte (1, 2). The PHA is a benign dominantly inherited defect of terminal neutrophil differentiation with a frequency at birth of 1:6000, due to mutations in the lamin B-receptor gene (3-5). The PHA can give rise to an apparent increase in neutrophil band forms, often confused with a left shift. The practical importance of identifying the PHA lies in distinguishing this defect from left shift that is more commonly associated with infections. The two lobes are joined by a thin bridge that is much thinner than that seen in a normal band form (6).

Some affected French-Canadian kindred reported as nuclei of their leukocytes had a pince-nez appearance (7). Genome wide linkage scan has mapped the PHA locus to 1q41 to q43, the region that contains the lamin B receptor gene. Abnormalities in sequence of Lamin B Receptor (LBR) gene results in a lack of LBR protein that is essential for chromatin-binding to nuclear membrane (8). The function of the neutrophil is normal in both heterozygous and homozygous individuals. The biochemical, metabolic, phagocytic, and bactericidal activities, as well as the random motility and response to chemotactic stimulus of neutrophils in patients with PHA were all equivalent to normal neutrophils. Although some studies believe neutrophil migration may be minimally impaired granulocytes function which is otherwise normal (9).



The homozygous state results in neutrophils that contain a single round eccentric nucleus with clumped chromatin. Homozygous forms are very rare in the human (10). Pelger-Huet cells can develop multiple lobes during states of vitamin B12 or folate deficiency. The cells return to their bilobate state once the vitamin deficiency is corrected (11). Colchicine and sulfonamides can induce the anomaly reversibly (12, 13). This so-called pseudo-Pelger cell has also been reported transiently during certain acute infections, in acute and chronic myeloid leukemia, and in myelofibrosis. This cell is especially prominent in the myelodysplastic syndromes (MDS). MDS typical granulocyte dysplasia was defined as granulocytes with bilobed pseudo PHA, erythrocyte dysplasia as tri-nucleus or nuclear budding erythrocytes (14). Transient occurrence of Pelger-Huet cells may be associated with tacrolimus toxicity due to drug interaction with fluconazole (15).

Mycophenolate mofetil (MMF) is a necessary but not sufficient condition for the development of the anomaly (16). Graft rejection episodes reported as a potential predisposing factor for the development of PHA. Some concluded that taxoid therapy with docetaxel and with paclitaxel produces transient PHA which peaks between days 3 and 9 of treatment (17). A patient with familial PHA, which accompanied tuberculosis and acute polyarthritis is described (18,19). The homozygote PHA in the rabbit also has chondrodystrophy (20). A 43-year old man who presented with depression had Pelger- Huet anomaly (21). Indeed, there are few reports about PHA with any problems or with organ dysfunctions.

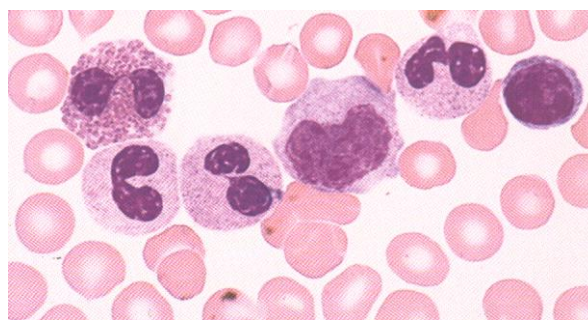
### Case presentation

An eight year-old boy with good consciousness with difficulty in respiration was admitted in Amirkola Hospital in Babol University of Medical sciences in Babol, Iran. The patient was not ill at presentation and he was not febrile either. After meticulous physical examination, MRI of brain, cervical, and lumbosacral spine, plain chest X-Ray, EEG, EMG, NCV and echo cardiograph to rule out of brain tumor, transverse myelitis, GBS has been done. Laboratory tests laboratory tests for infections, botulism and metabolic disorders has been done as well. The results of these investigations were normal. The patient was very cachectic too. It has started to develop 2 years ago. The patient had a normal neurodevelopment progress in his first 5 years of life.

He began to walk at eleven months. He was very active and run very fast as 2 years. He had an operation for right inguinal hernia when he was 3 years old. He had hearing loss when he was 4 years old. He began to have weight loss and cachexia when he was 5 years old. He got vision disturbance as myopia when he was 5 years too. He goes to elementary school now.

He does not have any siblings. He had apnea probably due to severe muscular atrophy. He could not eat anything because of this problem. Tracheotomy and mechanical ventilation have been done to him for about 60 days. He was fed by naso-gastric tube through this period. It led to one kilogram weight gain. He was discharged after 60 days hospitalization, and he is now being observed as an outpatient. Evaluation of ear and eye problems, brain MRI done. It was normal. The patient and his mother have 30% to 40% band and two lobes neutrophil with excessively coarse clumping of nuclear chromatin "Pelger-Huet cells" in peripheral blood smear (fig 1).

He and his mother have never had pulmonary or sinopulmonary infection. He is very clever and his intelligence quantity score is good. His height was 121 cm and his weight was 11kg.at presentation; he was very cachectic. White blood cellcount and its difference were as follows: WBC=15800/ml, Hb: 13, HCT=40.9, platelete=350.000, poly=45%, Ly-ph=18%, Band=5%, PHC=24%, Meta=5%, Meta=5% Mono=2%, EO=1%.



**Figure1. Peripheral blood smears of a patient with Pelger-Huët anomaly**

### Discussion

We were interested to report this case because the association of PHA with nerve optic atrophy, ear problem and disability was not reported in the world yet. We believe the general cause of these problems pertain to severe generalized muscular atrophy which progress gradually.

Although an unusual case of PHA has been reported in association with four generations of one family with late-onset progressive proximal muscular dystrophy (22). Ocular and skeletal abnormalities were documented in a samoyed male and its five offspring. Hematological abnormalities, found in repeated tests in all the dogs (23). Several problems in PHA presented in our patient were very rare. We could not find a special cause for these problems. We believe this is a rare association that has not been reported yet. His parents are not consanguine. Our patient has no medical history of infection. It was against the study of N. Suzuki et al. describing a patient with familial Pelger-Huet (PH) anomaly, that was accompanied by tuberculosis, and acute polyarthritis (24).

Investigations surrounding this case suggest that the immunological abnormalities may be associated with the PH anomaly and the tuberculosis, and that the complications may be related to the development of the acute polyarthritis. His mother who is 30 years old and a typical Pelger-Huet anomaly does not have any problems. This case was a late diagnosis of PHA that had uneventful clinical courses, blood smears with morphologic changes consistent with PHA were not initially noted. It can be explained by the fact that a rare anomaly and smears were not analyzed well. This case demonstrate the importance of complete evaluation of history, examination and laboratory data for accurate diagnosis. Although everyone knows that the patient is an unusual type of PHA with multiple organ dysfunctions.

We emphasize the evaluation of other cases of PHA to find other abnormalities that may be present or progress in future of his life. We should follow up all the patients with Pelger-Huet anomaly either they show muscular dystrophy or not.

Likewise, we should ask seriously if there is another association with this congenital anomaly or not. In summary, our patient is an unusual type of Pelger-Huet anomaly with multiple organ dysfunctions probably due to simultaneous muscular degenerative disease.

### Acknowledgements

This study was supported by grant from Pediatrics Research Center, Babol University of Medical Sciences. We would like to thank all the nurses of PICU ward who participated in this study.

### References

1. Allan R, Ezokovitz B. Hematologic Manifestations of Systemic Disease in Children of the Developing world. In: orkin SH, Fisher DE, Look T, et al. Nathan and Oski's Hematology of Infancy and Childhood. 7th edition. Philadelphia, USA: Sanders Elsevier 2009; P:1709.
2. Yamasowa Y, Fujii T, Tsuchitori K. The Pelger-Huët. Familial anomaly of leukocytes. *Blood* 1953; 8: 370-4.
3. Hoffmann K, Dreger CK, Olins AL, et al. Mutations in the gene encoding the lamin B receptor produce an altered nuclear morphology in granulocytes (Pelger-Huet anomaly). *Nat Genet* 2002; 31: 410-4.
4. Best S, Salvati F, Kallo J, et al. Lamin B-receptor mutations in Pelger-Huet anomaly. *Br J Haematol* 2003; 123: 542-4.
5. Skendzel LP, Hoffman GC. The Pelger anomaly of leukocytes: forty-one cases in seven families. *Am J Clin Pathol* 1962; 37: 294-301.
6. Tomonaga M. Nuclear abnormalities in Pelger-Huet anomaly; progress in blood cell morphology. *Rinsho Byori* 2005; 53: 54-60.
7. Rioux E, St-Arneault G, Brosseau C. The Pelger-Huet anomaly of leukocytes: description of a Quebec kindred. *Can Med Assoc J* 1968; 99: 621-4.
8. Zwerger M, Herrmann H, Gaines P, Olins AL, Olins DE. Granulocytic nuclear differentiation of lamin B receptor-deficient mouse EPRO cells. *Exp Hematol* 2008; 36: 977-87.
9. Johnson CA, Bass DA, Trillo AA, Snyder MS, DeChatelet LR. Functional and metabolic studies of polymorphonuclear leukocytes in the congenital Pelger-Huet anomaly. *Blood* 1980; 55: 466-9.
10. Handl J. Leucocyte anomalies. In: Handl JH (ed). *Textbook of Hematology*, 2nd ed. Little Brown: Boston 1996; p: 788-9.
- 11 Taylor RL. Pelger-Huet anomaly and megaloblastic anemia. *Am J Clin Pathol* 1973; 60: 932-5.
12. Dorr AD, Moloney WC. Acquired pseudo-Pelger anomaly of granulocytic leukocytes. *N Engl J Med* 1959; 261:742-6.
13. Kaplan JM, Barrett O Jr. Reversible pseudo-Pelger anomaly related to sulfisoxazole therapy. *N Engl J Med* 1967; 277:421-2.
- 14 Li X, Wu L, Ying S, Chang C, Pu Q. Clonality investigation of morphologically dysplastic

- hematopoietic cells in myelodysplastic syndrome marrows. *Int J Hematol* 2008; 87:176-83.
15. Gondo H, Okamura C, Osaki K, et al. Acquired Pelger-Huët anomaly in association with concomitant tacrolimus and fluconazole therapy following allogeneic bone marrow transplantation. *Bone Marrow Transplant* 2000; 26: 1255-7.
  16. Asmis LM, Hadaya K, Majno P, et al. Acquired and reversible Pelger-Huët anomaly of polymorphonuclear neutrophils in three transplant patients receiving mycophenolate mofetil therapy. *Am J Hematol* 2003;73: 244-8.
  17. Juneja SK, Matthews JP, Luzinat R, et al. Association of acquired Pelger-Huet anomaly with taxoid therapy. *Br J Haematol* 1996; 93: 139-41.
  18. Suzuki N, Yasutake T, Ushiyama O, et al. Familial Pelger-Huet anomaly accompanied by tuberculosis and complicated by acute polyarthritis. *Scand J Rheumatol* 1995; 24:319-20.
  19. Cicchitto G, Parravicini M, De Lorenzo S, Di Pisa G, Malacrida A. Tuberculosis and Pelger- Huët anomaly. Case report. *Panminerva Med* 1999; 41: 367-9.
  20. Nachtsheim H. The Pelger-anomaly in man and rabbit; a mendelian character of the nuclei of the leucocytes. *J Hered* 1950; 41: 131-7.
  21. Anand M, Kumar R, Raina V. Pelger-Huet anomaly: A case report. *Indian J Pathol Microbiol* 2007; 50: 661-2.
  22. Schneiderman LJ, Sampson WI, Schoene WC, Haydon GB. Genetic studies of a family with two unusual autosomal dominant conditions: muscular dystrophy and Pelger-Huet anomaly. Clinical, pathologic and linkage considerations. *Am J Med* 1969; 46: 380-93.
  23. Aroch I, Ofri R, Aizenberg I. Haematological, ocular and skeletal abnormalities in a samoyed family. *J Small Anim Pract* 1996; 37: 333-9.
  24. Suzuki N, Yasutake T, Ushiyama O. Familial Pelger-Huet Anomaly Accompanied by Tuberculosis and Complicated by Acute Polyarthritis. *Scand J Rheumatol* 1995; 24: 319-20.