

Neha Agrawal (MD)¹
Tuhin Santra (MD)^{1*}
Arnab Kar (MD)²
Pradipta Guha (MD)¹
Mita Bar (MD)¹
Apu Adhikary (MD)³
Sumana Datta (MD)⁴

1. Department of Medicine, Calcutta National Medical College and Hospital, Kolkata, India.
2. Department of Medicine, Gangarampur Subdivisional Hospital, India.
3. Department of Medicine, North Bengal Medical College & Hospital, India.
4. Department of Family Medicine, Calcutta Medical Research Institute, Kolkata, India.

*** Correspondence:**

Tuhin Santra, Department of Medicine, Calcutta National Medical College & Hospital, 24/32, Gorachand Road, Entally, Kolkata-700014.

E-mail: dralka.y@gmail.com

Tel: 0091 9432106081

Fax: 0091

Received: 30 May 2015

Revised: 24 Aug 2015

Accepted: 30 Aug 2015

Deep vein thrombosis in a patient of adenomatous polyposis coli treated successfully with aspirin: A case report

Abstract

Background: Deep vein thrombosis is an important cause of morbidity and mortality. However, its association with adenomatous polyposis coli is extremely rare. Here we present an interesting case of deep vein thrombosis associated with adenomatous polyposis coli.

Case Presentation: A 15 year old female who was having fever and diarrhea for 5 months developed bilateral asymmetric painful swelling of lower limbs for 1 month. Doppler ultrasound of lower limbs revealed presence of thrombosis from inferior vena cava up to popliteal vein. Colonoscopy and biopsy were suggestive of adenomatous polyposis coli. However, she could not tolerate anticoagulant therapy and was put on aspirin therapy for 6 months to which she responded well with the resolution of thrombus.

Conclusion: Role of aspirin therapy may be considered whenever a patient of venous thrombosis cannot tolerate anticoagulant therapy.

Keywords: Deep vein thrombosis, Adenomatous polyposis coli, Diarrhea, Aspirin.

Citation:

Agrawal N, Santra T, Kar A, et al. Deep vein thrombosis in a patient of adenomatous polyposis coli treated successfully with aspirin: A case report. *Caspian J Intern Med* 2016; 7(2):142-145.

Caspian J Intern Med 2016; 7(2):142-145

Venous thromboembolism is an important cause of hospital acquired morbidity and mortality (1). Its association with adenomatous polyposis coli is a rare event (2, 3). Malignancy or major operative procedure associated with colonic polyp may predispose to thromboembolic event (2). There has been previously published few reports of diarrhea associated with deep vein thrombosis (4-6). Etiology of diarrhea in those cases was unrelated to colonic polyp. However, association of deep vein thrombosis with non-malignant colonic polyp presenting with diarrhea is an extremely rare event with a report of only one case in previous English literature (3). Mainstay of therapy of deep vein thrombosis is anticoagulation. However, fatal bleeding episode following anticoagulation in our patient lead to withdrawal of anticoagulation therapy. The patient was treated successfully with low dose aspirin therapy (75mg/day) with complete resolution of thrombus.

Case Presentation

A 15-year-old unmarried female presented to us with complain of asymmetric onset lower limb swelling for last 1 month. The swelling initially involved the left lower limb and for last 1 week she had also developed right lower limb swelling. The swelling which was initially painless later became painful.

She was also having low grade irregular fever for last 5 months along with small amount of non-foul smelling mucus containing recurrent episodes of diarrhea for the same duration along with a history of significant weight loss. She had an episode of hematochezia 1 day after admission. There was no history of abdominal pain, vomiting, abdominal distension, facial puffiness, oliguria, bleeding from any other sites, joint pain, skin rash, recent contact with tuberculosis, recent surgery or prolonged immobilization. She had mild pallor and her body mass index (BMI) was 17.5 kg/m². She had bilateral pitting pedal edema along with raised local temperature and a positive Homans' sign and Moses' sign.

Her routine investigations revealed a hemoglobin level of 8.9 g/dl, total leucocyte count (TLC) of 10,500/mm³, erythrocyte sedimentation rate (ESR) of 6 mm. in 1st hour, low albumin level (2.5g/dl) and serum creatinine of 0.9 mg/dl. Stool examination revealed presence of mucous, blood and pus cells. Chest x-ray, ultrasonography of whole abdomen was unremarkable. She was found to be HIV negative. Duplex color doppler of both lower limbs revealed presence of intraluminal thrombus involving the inferior vena cava (IVC) from the level just beyond the origin of left renal vein up to the popliteal vein. Contrast enhanced CT (computed tomography) of abdomen was done which confirmed the presence of IVC (inferior vena cava) thrombosis (figure 1).

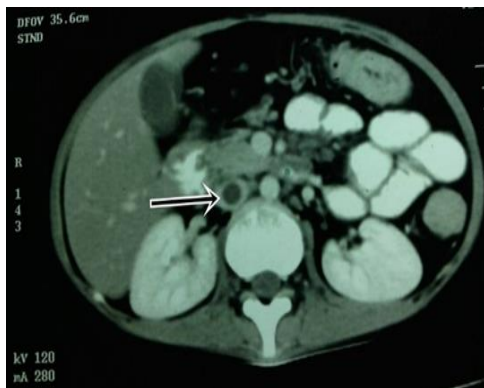

Figure 1. CT abdomen showing thrombus in IVC

Colonoscopy revealed presence of multiple polyps, may be up to 100 in number with size being 0.5-1 cm. of diameter up to the level of cecum (Figure 2). Biopsy from the sigmoid polyp revealed adenomatous polyp without any evidence of malignancy (figure3). Her prothrombin time (P time), activated partial thromboplastin time (aPTT) and fibrinogen level was within normal limit and she had a raised fibrin

degradation product (FDP) level (2671.2 ng/ml). Her antinuclear antibody (ANA), anti-double stranded DNA (anti ds-DNA), lupus anticoagulant and anticardiolipin antibody was negative and she had a normal homocysteine and protein C and protein S level.

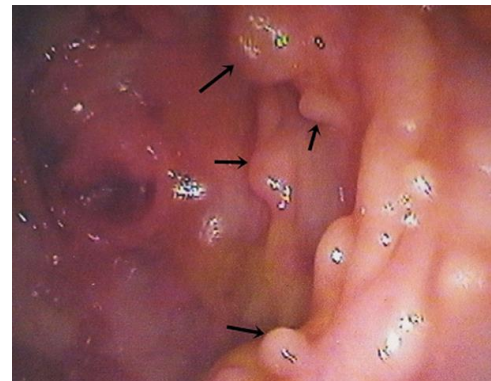


Figure 2. Multiple polyps in colon

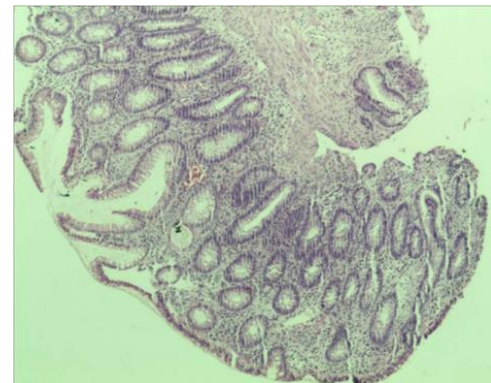


Figure 3. Biopsy from sigmoid polyp revealing adenomatous polyp without any evidence of malignancy

So, she was diagnosed to have adenomatous polyp with deep vein thrombosis and she was put on injection enoxaparin and tablet warfarin. But 2 days after she developed life threatening hematochezia and patient went to shock and the therapy was stopped. Repeat P time was normal. The patient was successfully resuscitated and after hematochezia was stopped, she was put on tablet warfarin but again she developed hematochezia. Thus, both the enoxaparin and warfarin therapy were discontinued. After control of hematochezia she was then put on a trial of aspirin therapy (75 mg/day). No bleeding manifestations occurred and repeat doppler ultrasound study after 2 months revealed partial recanalization within the thrombus with resolution of

her symptoms. Doppler ultrasound after 4 months revealed complete recanalization and aspirin therapy was continued for a total duration of 6 months.

Discussion

Venous thromboembolism is associated with several risk factors. Prolonged immobility, major surgery, malignancy, trauma, presence of antiphospholipid antibody, use of oral contraceptives are important leading causes of thromboembolic event (7, 8).

It may occur in association with other chronic inflammatory conditions like inflammatory bowel disease, tuberculosis or with malabsorption syndromes which present with abdominal symptoms like diarrhea, pain abdomen, ascites (5, 6, 9). However, to the best of our knowledge, deep vein thrombosis associated with non-malignant colonic polyp has been described only once in previous English literature (3).

In that case, deep vein thrombosis was postulated secondary to immobility associated with poor health which is not applicable to our case. Dehydration associated with diarrhea might be an explainable risk factor for development of deep vein thrombosis in our patient (10).

Again, major bleeding episode associated with anticoagulant therapy prevented its further use in our patient. Aspirin has been tried as thromboprophylaxis for venous thromboembolism in high risk patients (11, 12). However, its use for venous thrombosis is still not recommended although it is recommended for arterial thromboembolic event. Aspirin which suppresses cell proliferation by inhibiting prostaglandin synthesis has been assessed as possible inhibitors of colon cancer (13). We treated our patient successfully with aspirin 75 mg/day for 6 months with complete resolution of symptoms and thrombus.

Conclusion

This is a well-documented clinical, radiological and histological case report of recognized association of deep vein thrombosis with adenomatous polyposis coli. Role of aspirin therapy may be considered whenever a patient of venous thrombosis cannot tolerate anticoagulant therapy.

Acknowledgments

The authors thank the patient who agreed and allowed us to present her in this paper.

Conflict of Interests: The authors have no conflict of interests or financial disclosures.

References

1. Butcher JH, Pasi KJ. Fatal postoperative pulmonary embolism in mild haemophilia. *Haemophilia* 2006; 12: 179-82.
2. Meshikhes AW, Al-Ghazal T. Portal vein thrombosis after restorative proctocolectomy for familial adenomatous polyposis and sigmoid cancer. *Case Rep Gastroenterol* 2012; 6: 124-30.
3. Longcroft-Wheaton G, O'Brien J, Woolf K. Hypoalbuminaemia and colonic polyps: a case of protein-losing enteropathy with cap polyposis? *Br J Hosp Med (Lond)* 2007; 68: 444-5.
4. Javid Bhat K, Bhat S, Dutt K, Gupta S, Jeelani Samoon H. Chronic diarrhea, eosinophilic ascites, acute pancreatitis and deep venous thrombosis: a case report. *Caspian J Intern Med* 2014; 5: 182-5.
5. Kim W, Kang B, Kim BW, et al. Crohn's disease initially accompanied by deep vein thrombosis and ulnar neuropathy without metronidazole exposure. *Gut Liver* 2013; 7: 252-4.
6. Beyan E, Pamukcuoglu M, Beyan C. Deep vein thrombosis associated with celiac disease. *Bratisl Lek Listy* 2009; 110: 263-4.
7. Freedman JE, Loscalzo J. Arterial and venous thrombosis. In: Longo DL, Fauci AS, Kasper DL, Hauser SL, Jameson JL, Loscalzo J. (eds). *Harrison's principles of internal medicine*. 18th ed. New York: McGraw Hill Inc 2012; pp: 983-8.
8. Heit JA, Silverstein MD, Mohr DN et al. Risk factors for deep vein thrombosis and pulmonary embolism: a population-based case-control study. *Arch Intern Med* 2000; 160: 809-15.
9. Gupta R, Brueton M, Fell J, Lyall H. An Afghan child with deep vein thrombosis. *J R Soc Med* 2003; 96: 289-91.
10. Zitomersky NL, Verhave M, Trenor CC 3rd. Thrombosis and inflammatory bowel disease: a call for improved awareness and prevention. *Inflamm Bowel Dis* 2011; 17: 458-70.
11. Pulmonary Embolism Prevention (PEP) Trial Collaborative Group. Prevention of pulmonary embolism and deep vein thrombosis with low dose aspirin:

- Pulmonary Embolism Prevention (PEP) trial. *Lancet* 2000; 355: 1295-302.
12. Collaborative overview of randomised trials of antiplatelet therapy--III: Reduction in venous thrombosis and pulmonary embolism by antiplatelet prophylaxis among surgical and medical patients. Antiplatelet Trialists' Collaboration. *BMJ* 1994; 308: 235-43.
13. Mayer RJ. Gastrointestinal tract cancer. In: Longo DL, Fauci AS, Kasper DL, Hauser SL, Jameson JL, Loscalzo J. (eds). *Harrison's principles of internal medicine*. 18th ed. New York: McGraw Hill Inc 2012; pp: 764-76.