

Kayvan Kiakujori (MD)^{*1}
Naser Kamalian (MD)²

1- Department of
Otolaryngology Babol Medical
University Babol, Iran
2- Department of Pathology
Tehran Medical University
Tehran, Iran.

*** Correspondence:**

Kayvan Kiakojuri, MD.
Assistant Professor of
Otolaryngology. Department of
Otolaryngology Ayatollah
Rouhani Hospital, Babol
Medical University
Post Code: 47176-47754
E-mail: kia_ko13358@yahoo.com
Tel: 01112252071
Fax: 01112227667

Received: Nov 7 2009
Revised: Dec 9 2009
Accepted: Jan 4 2010

Vocal cord lesion due to lichen planus

Abstract

Background: Lichen planus is a skin disease that rarely involves mucus membrane.

Case: In this study, we introduced a rare case of lichen planus of the right vocal cord in a 51- year -old male presented with hoarseness. The lesion started two years ago and the hoarseness became progressive. There were not any lesions found in his buccal mucosa and skin. The biopsy of the lesion showed lichen planus in his right vocal cord.

Conclusion: Lichen planus may rarely involve the vocal cord.

Key words: Lichen planus, Vocal cord, Hoarseness.

Casp J Intern Med 2010; 1(1): 36-38.

Hoarseness and mild dysphagia in adults are seen in many infectious and non-infectious diseases. The common causes among the infectious diseases tuberculosis and fungal infection are among the infectious diseases, tuberculosis and fungal infection are common causes (1-6). Systemic diseases like RA (7-9), sarcoidosis (10-11), Wegner granulomatosis (12) and amiliodosis (13,14) are reported to be associated with hoarseness. Vocal cord nodule, laryngeal polyps and hemorrhagia intracordal cyst is caused by the trauma of the vocal cord and also seen in loquacious personality. Brodniz et al, reported nodule polyp and polypoid thickening in 45% of 977 cases with impairment of the voice (15). The lesion was benign in 50% of the 2618 cases with vocal impairment (16). Squamous papillomas is the most common benign tumor of the larynx and is seen in 18/100000 adults' normal population (17). Vascular neoplasm is the most common vascular tumor in larynx (18). Vocal cord lesion due to lichen planus has not been reported in the medical literature. We present a case of vocal cord lesion due to lichen planus.

Case presentation

A 51- year -old man was admitted to the hospital due to a progressive hoarseness with mild odynophagia that started two years ago. In indirect laryngoscopy-stroboscopy, a white lesion with undefined margin was seen in the right anterior commissure of the larynx (Figure 1). The chest x-ray was normal and so was the blood chemistry, but the PPD test was positive. The patient was not a drinker or a smoker. The oral cavity, and pharynx was normal, The esophagoscopy done was also normal. There were not any lesions throughout the body and the skin was intact. Using the general anesthesia, direct laryngoscopy was performed and so was the biopsy of the lesion. The pathologic examination of the lesion was reported to be lichen planus of the right vocal cord involvement (Figure 2).

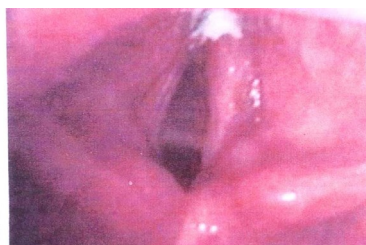

Fig 1. Stereoboscopy of right vocal cord lesion

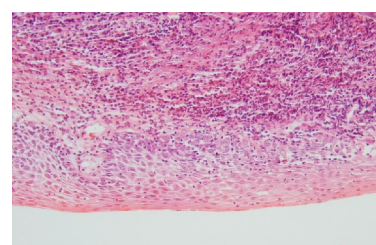


Fig 2. Pathology of the vocal cord lesion in Lichen Planus

Discussion

In this study, we present an unusual case of Lichen planus of vocal cord without any evidence of the involvement of buccal mucosa, pharynx, lip and skin. Lichen planus is a mucocutaneous lesion and an immunological disorder of T-cells with a prevalence of 0.2% to 2% (19). The disease includes two clinical types: erosive and reticularis. Only the erosive type is usually painful and its common sites of involvement are buccal mucosa, gum and tongue. The lesions are erythematic, ulcerative with surrounding keratotic materials (19-20). In one study, 29 (4%) cases of squamous cell carcinoma developed among 725 cases patients with lichen planus of the buccal mucosa and lip (19). The erosive type responded to steroid therapy. Although TB laryngitis was reported by other researchers (1-3). Tuberculosis lesion is nodular or mucosal ulceration forms and is seen in the elderly men with previous history of consumption of alcohol or smoking. Cryptococcosis, coccidiomycosis and histoplasma capsulatum are reported to be the causes of laryngeal lesions in areas endemic with this mycosis, but candida albicans is seen in individuals with immune deficiency (5-6). Mucosal ulceration, erythema and leucoplakia of vocal cord are the most common forms of laryngeal lesions in infectious etiology (5). Several studies of vocal cord lesions with systemic diseases like RA, sarcoidosis, wegner granulomatosis, and amiloidosis were reported in the medical literature (7-12). Involvement of vocal cord is seen in 23% cases with wegner granulomatosis and 50% cases with amiloidosis (12-14). Squamous papilloms is the most common benign tumor of the larynx and is seen in 18/100000 adults in normal population (17). Vascular neoplasm is the most common vascular tumor in larynx (18). The vocal cord nodule, laryngeal polyps and hemorrhagia intracordal cyst are caused by the trauma of the vocal cord and in loquacious personality, but hoarseness in elderly cases may be due to malignancy. In conclusion, the isolated lesion of Lichen planus of vocal cord without any evidence of common sites of involvement may be seen in patients. Therefore, Lichen planus should be considered in differential diagnosis of vocal cord lesions.

Acknowledgement

The authors would like to thank the personnel of the Department of Otolaryngeal diseases. Special thanks to Dr.

M.R. Roshan for generously sharing his expertise in this manuscript.

Reference

1. Kandiloros DC, Nikolopoulos TP, Fereridis EA, et al. Laryngeal tuberculosis at the end of the 20 th century. *J Laryngol Otol* 1997; 111: 619-21.
2. Nishiike S, Irifune M, Doi K, Sawada T, Kubo T. Laryngeal tuberculosis: a report of 15 cases. *Ann otol Rhinol laryngol* 2002; 111: 916-8.
3. Ramadan HH, Tarazi AE, Baroudy FM. Laryngeal tuberculosis: presentation of 16 cases and review of the literature. *J Otolaryngol* 1993; 22: 39-41.
4. Soda A, Rubio H, Salazar M, Ganem J, Bcrlanga D, Sanehez A. Tuberculosis of the larynx: clinical aspects in 19 patients. *Laryngoscope* 1989; 99: 1147-50.
5. Forrest LA, Weed H. Candida laryngitis appearing as leukoplakia and GERD. *J Voice* 1998; 12: 91-5.
6. Tashjian LS, Peacock JE JR. Laryngeal candidiasis. Report of seven cases and review of literature. *Arch Otolaryngol* 1984; 110: 806-9.
7. Lofgren RH, Montgomery WW. Incidence of laryngeal involvement in rheumatoid arthritis. *N Engl J Med* 1962; 267: 193-5.
8. Brooker DS. Rheumatoid arthritis Otorhino laryngological manifestations. *Clin Otolaryngol Allied Sci* 1988; 13: 239-46.
9. Montgomery WW. Cricoarytenoids arthritis. *Laryngoscope* 1963; 73: 801-36.
10. Weisman RA, Canalis RF, Powell WJ. Laryngeal sarcoidosis with airway obstruction. *Ann Otol Rhinol Laryngol* 1980; 89: 58-61.
11. Dean CM, Sataloff RT, Hawkshaw MJ, Pribikin E. Laryngeal sorcoidosis *J Voice* 2002; 16: 283-8.
12. Langford CA, Sneller MC, Hallahan CW, et al. Clinical features and therapeutic management of subglottic stenosis in patients with wegener`s granulomatosis. *Arthritis Rheum* 1996; 39: 1754-60.
13. Lowis J, Olsen KD, Kurtin PJ, Kyle RA. Laryngeal amyloidosis: A clinicopathologic and immunohistochemical review. *Otolaryngol Head Neck Surg* 1992; 106: 372-7.
14. Piazza C, Cavaliere S, Foccoli P, et al. Endoscopic management of laryngo-tracheobronchial amyloidosis:a

- series of 32 patients. *Eur Arch Otorhinolaryngol* 2003; 206: 349-54.
16. Bastian RW. Benign vocal fold mucosal disorders In: Cummings Otolaryngology head and neck surgery. 4th ed, Mosby, Philadelphia 2005: 2150-86.
17. Derkay CS. Task force on recurrent respiratory papillomas. A preliminary report. *Arch Otolaryngol Head and Neck Surg* 1995; 121: 1386-91.
18. Fechner RE, Cooper PH, Mills SE. Pyogenic granuloma of the larynx and trachea: a causal and pathologic misnomer for granulation tissue. *Arch Otolaryngol* 1981; 107: 30-2.
15. Brodnitz FS. Goals, results and limitations of vocal rehabilitation. *Arch Otolaryngol* 1963; 77: 148-56.
19. Sciubba JJ. Oral mucosal lesions. In: Cummings Otolaryngology head and neck surgery. 4th ed, Mosby, Philadelphia 2005; 1448-92.
20. Andres WE. Disease of the skin. *Clinical Dermatology*. 9th ed 2000; 267.

This document was created with Win2PDF available at <http://www.daneprairie.com>.
The unregistered version of Win2PDF is for evaluation or non-commercial use only.